


AWM4
Australian Imperial Force unit war diaries,
1914-18 War

Medical, Dental & Nursing

Item number: 26/89/7

Title: Desert Mounted Corps Operating Unit

December 1918



AWM4-26/89/7

WAR DIARY

or INTELLIGENCE SUMMARY.

(Erase heading not required.)



Army Form C. 2118.

Instructions regarding War Diaries and Intelligence Summaries are contained in F. S. Regs., Part II. and the Staff Manual respectively. Title pages will be prepared in manuscript.

Summary of Events and Information

Remarks and references to Appendices

DESERT CORPS OPERATING UNIT

December 1918

HOMS, Aus. Rec. Sta.

General remarks

I beg leave to submit my report for the month of December 1918 - I am still attached to the Receiving Station at Homs which is being carried on by a section of the 5th L.H.F. Amb. As well as attending all surgical work which comes along, I am in charge of 3 or 4 wards here and have at various periods during the month carried out other work, such as Desert-Corps sick parades, 14th Regiment sick parades & attending to the wounded & sick prisoners at the Durrkirk Hospital etc. I am now in the position of having only 2 members of my unit left - 1st Corp. Barnes & Pvt. Blaw - Early in month (3rd) both Pvt. Sibley & Pvt. Alford reported sick, & were found to be suffering from Malana (B.T.) & were evacuated to Egypt - Later Driver Robinson was evacuated with Leishmaniasis of arm, & the driver of the G.S. Wagon & his native with his team were taken back by Des Corps Head Quarters. I was notified that Corp. Richards was on the way to rejoin the unit but so far he has not reported. The autoclave again went wrong

11 JAN 1919

* HEADQUARTERS *

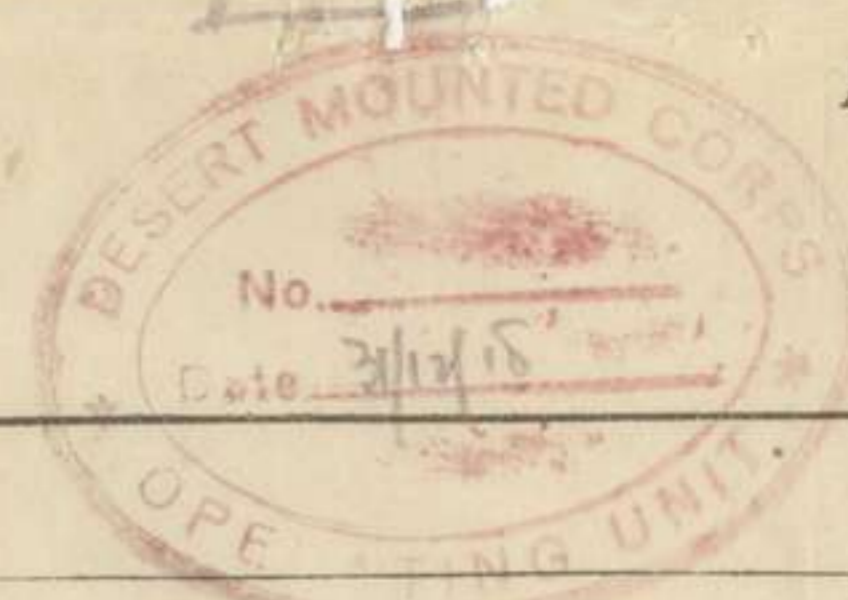WAR DIARY

or

INTELLIGENCE SUMMARY.

(Erase heading not required.)

Army Form C. 2118.



Instructions regarding War Diaries and Intelligence Summaries are contained in F. S. Regs., Part II. and the Staff Manual respectively. Title pages will be prepared in manuscript.

Summary of Events and Information

Remarks and references to Appendices

Place Date Hour

HOMS

but - I had it repaired by the M.R.U. Here it is now in good working order. As, after the evacuation of the Car driver, no one was available to take his place & look after the car, arrangements were made with the A.D.S.T. (Major Price) to have it stored with the M.R.U. (No 3) & it is now there - all movable gear, as well as four new tyres received, were placed inside the car, which was then locked up for safety. With spare tubes & tyres received, & the slight-repairs done, as well as electric light bulbs received from the Aust. Red Cross the car is now ready for the road at any time. The balance of gear taken from the G.S. wagon is now in the hospital & includes the E.P. tent - etc. During the month I forwarded to the D.D.M.S. my recommendations for inclusion of deserving members of the Unit in the Peace Gazette. Re the special work of this Unit; nothing very much doing although a most interesting case of malignant pustule (anthrax) was met with & successfully treated, as well also as one of Ludwig's Angina also operated upon with quite a dramatic recovery. Other minor cases attended to as per appendix attached -

Re. Surgical work

W.H. Jefferys Capt. of the D.C. of Unit

Date	No	Unit	Rank	Name	Disease	Remarks	Result
3/12/18	028048	5 th Cav Div A.O.C.	Priv.	WEBSTER R.B.	G.S. wound left arm side	accidental revolver bullet wound thro' thro' left forearm b, thro' left chest (Empyema & haemula) bullet removed from suprascapular region - Had secondary pleural effusion + chest had to be emptied w/ice of bloody fluid (about 3 1/2 pt)	Evac'd down well
8/12/18	273282	DES Corp Squad	Priv.	FRASER J.	Parapneumon	A nasty condition of peris with much oedema etc - under anesthetic punctures reduced in	Evac'd well
14/12/18	11279	AVE.	Sgt	SPINETTO O.	Necrosis of Pharynx	necrosis of middle pharynx after whitlow - bone removed in - Some ankylosis of joint.	Evac'd well
15/12/18	15223	ASC Exp natives		HASSEN OHRAM	Ludwigs Angina	a most interesting case - rapidly sporadic cellulitis of neck face + upper chest - impeded breathing & man desperately ill & looking like dying very soon - used anesthetic multiple incisions & much sloughing pus struck in mid line over Trachea - in few hours, from what looked a dying man one had a native asking for cigarette - the benefit of op	Evac'd in unit well

W. H. H. H. H.
des & of unit





Date	No	Unit	Rank	Name	Disease	D.C. of unit - Remarks	Results
23/12/18		Interpreters		MICHEL YAZISI	Phimosis	a bad phimosis with ulcer in Den of glands - slit-up cleaned Eti - cond ⁿ not in fit state for excise - ② Axillary abscess opened	Evac ^d well
27/12/18	B 491	Indian Pioneers 7/107	Sepoy	NANUK SINGH	Malignant Pustule of face Anthrax	A very nasty rapidly spreading anthrax pustule on side of face in region of R. parotid gland. Discharge confirmed by microscope - under anaesthetic the whole pustule cut out - scraped - contaminated by ac Carb pen one or 2 sutures lipped in - did very well	Evac ^d well
29/12/18	361215	1032 Labor Corps attach DMC	Pvt.	SMART W.	Acute Periostitis Tibia	after injury - well treated to bone - pus Evac ^d under local - dressing very well when Evac ^d	Evac ^d well
26/1/19	230151	Dorsu VED	Spr.	ALFORD A.J	Burns of face & neck	extensive burns face & neck from explosion of mortar - of 1 1/2 12" depress shock in - very bad for some days now doing very well - spirit cleaning wound dressing	Doing well
26/1/19	391302	G.H.2 Cavalry etc. 31/12/18	Spr.	DIXON E.L	Fracture base skull	through in with fracture escape of C.S. fluid from middle ear - did very well e spirit cleaning in - 17911 Drysdale Capt of 10th	Evac ^d well

SERIALIZED
 MOUNTED
 G.H.2
 31/12/18
 17911 Drysdale Capt of 10th